

Balloon-TACE

Since the first particle-based tumor embolization procedure in the early 1970s, embolization agents have undergone significant improvements. Over the same period, the development of devices capable of delivering improved tumor fill has been lacking, even though tumor fill is the single most important factor in achieving a CR^{1,2}. The studies below used both the Occlusafe balloon microcatheter and the Sniper microcatheter. Occlusafe studies may not represent Sniper performance. Please refer to the References below.

Data based on a meta-analysis of six two-arm retrospective studies using the Occlusafe balloon microcatheter. The sniper device was not evaluated in these studies, and therefore, Sniper performance may not reflect these results.

On Average, Balloon-TACE Improves CR on the First Procedure by 1.5X

Eight Clinical Studies with 941 Patients are Presented Below

2-Arm Studies, Balloon vs Standard Microcatheter

Golfieri, 2021³

Multi Center, 2-Arm Retrospective

530 patients (p = 0.026)

B-cTACE/B- DEB-TACE Improve CR by **40%**

Retreatment Rate at 6 months:

B-TACE 10%, Standard Micro 22% (**120% Better**)

(Balloon Catheter was Occlusafe)

Irie, 2016⁴

2-Arm Retrospective

77 patients, p = 0.016

B-cTACE Improves CR by **37%**

100% Objective Response

5 Year Survival Improved by **53%**

(Balloon Catheter was Occlusafe)

Arai, 2015⁵

2-Arm Retrospective,
97 patients (p < 0.05)

B-cTACE Improves CR by **39%**

Disease Progression Reduced from **25% to 4%**

(Balloon Catheter was Occlusafe)

Lucatelli, 2021⁶

2-Arm Retrospective 97 patients (p < 0.05)

B-DEB-TACE Improves CR by **39%**

(Balloon Catheter was Occlusafe)

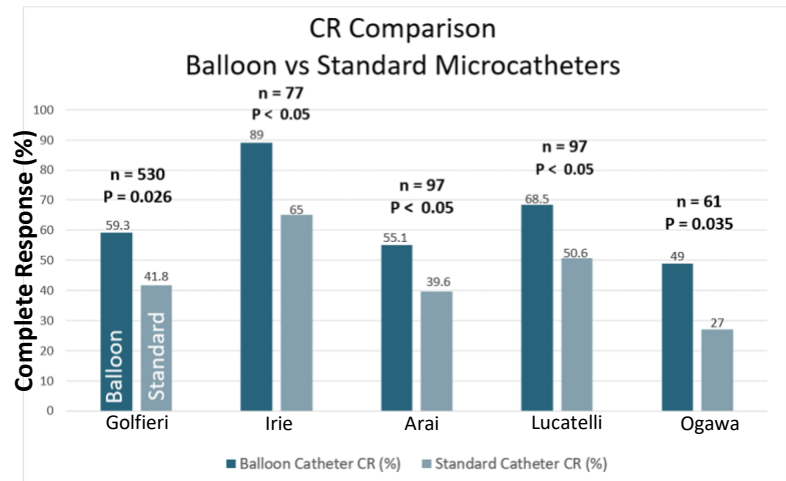
Ogawa, 2016⁷

2-Arm Retrospective

61 patients (p = 0.035)

B-cTACE Improves CR by **81%**

(Balloon Catheter was Occlusafe)



1-Arm Studies

Lee, Madoff, 2021⁸

1-Arm Retrospective, 31 patients

74% CR, 95% OR (p < 0.05)

100% Disease Control

(Balloon Catheter was Sniper)

Lucatelli, 2019⁹

1-Arm Retrospective B-DEB-TACE
22 patients

100% Objective Response

(Balloon Catheter was Occlusafe)

Goldman, Fischman, 2018¹⁰

1-Arm Retrospective, 26 patients

60% CR (p < 0.05)

100% Disease Control

(Balloon Catheter was Sniper)

Summary

Eight B-TACE Clinical Studies, including almost 1000 patients from the US, Japan & Italy are **consistent in demonstrating a remarkable rate of complete response at the first procedure that is 1.5 times better than a standard microcatheter**. This is prognostic for a > 50% improvement in 5-year survival⁸ which was also demonstrated by [Irie, 2016](#)⁴ Rev C

References

1. **Kim DY**, Ryu HJ, Choi JY, Park JY, Lee DY, Kim BK, Ahn SH, Chon CY, Han KH. Radiological response predicts survival following transarterial chemoembolization in patients with unresectable hepatocellular carcinoma. *Alimentary Pharmacology and Therapeutics* (2012) 35:1343-1350. (Balloon Microcatheter used was the Occlusafe™, Terumo Medical Corporation)
2. **Miyayama S**, Matsui O, Yamashiro M, Ryu Y, Kaito K, Ozaki K, Takeda T, Yoneda N, Notsumata K, Toya D, Tanaka N, Mitsui T. Ultraslective transcatheter arterial chemoembolization with a 2-f tip microcatheter for small hepatocellular carcinomas: relationship between tumor recurrence and visualization of the portal vein with iodized oil (2007). (Balloon Microcatheter used was the Occlusafe™, Terumo Medical Corporation)
3. **Golfieri R**, Bezzi M, Verset G, Fucilli F, Mosconi C, Cappelli A. *Cardio Intervent Radiol* (2021) <https://doi.org/10.1007/s00270-021-02805-5>. (Balloon Microcatheter used was the Occlusafe™, Terumo Medical Corporation)
4. **Irie T**, Kuramochi M, Kamoshida T, Takahashi N. Selective balloon-occluded transarterial chemoembolization for patients with one or two hepatocellular carcinoma nodules: retrospective comparison with conventional super-selective TACE. *Hepatology Research* (2016) 46:209-214. (Balloon Microcatheter used was the Occlusafe™, Terumo Medical Corporation)
5. **Arai H**, Abe T, Takayama H, et al. Safety and efficacy of balloon-occluded transcatheter arterial chemoembolization using miriplatin for hepatocellular carcinoma. *Hepatology Research* (2015) 45: 663-666.
6. **Lucatelli P**, De Rubeis G, Rocco B, Basilio F, Cannavale A, et al. Balloon occluded TACE (B-TACE) vs DEM-TACE for HCC: a single center retrospective case control study. *BMC Gastroenterology* (2021) 21:55 1-9. (Balloon Microcatheter used was the Occlusafe™, Terumo Medical Corporation)
7. **Ogawa M**, Takayasu K, Hirayama M, et al. Efficacy of a microballoon catheter in transarterial chemoembolization using miriplatin, a lipophilic anticancer drug: short-term results. *Hepatology Research* (2016) 46: E60-69. (Balloon Microcatheter used was the Occlusafe™, Terumo Medical Corporation)
8. **Lee KS**, Madoff DC. Segmental balloon-occluded transarterial chemoembolization of hepatocellular carcinoma. SIR 2021, Abstract. (Balloon Microcatheter used was the Sniper®, Embolx, Inc.)
9. **Lucatelli P**, Corradini LG, De Rubeis G, Rocco B, Bassilico R, Cannavale A, et al. Balloon-occluded transcatheter arterial chemoembolization (b-TACE) for hepatocellular carcinoma performed with polyethylene-glycol epirubicin-loaded drug-elution embolics: safety and preliminary results. *Cardiovasc Intervent Radiol* (2019) 42:853-862. (Balloon Microcatheter used was the Occlusafe™, Terumo Medical Corporation)
10. **Goldman D**, Singh M, Patel R, et al. Balloon-Occluded Transarterial Chemoembolization (B-TACE) for the Treatment of Hepatocellular Carcinoma: A Single Center U.S. Preliminary Experience. *J Vasc Interv Radiol* (2019) 30:342–346. (Balloon Microcatheter used was the Sniper®, Embolx, Inc.)